



PRESENTING CLINICAL SIGNS

History: Grade 3/6 left-sided murmur. Recent coughing episode.

DATE

11/2/22

ECHOCARDIOGRAPHIC FINDINGS

2D, M-mode, and Doppler study.

PERFORMED BY:

Jessica Miller

INTERPRETED BY

Keith Blass, DVM,
MS, DACVIM
(Cardiology)

Left atrial size is normal. The mitral valve leaflets are mildly thickened, and a mild jet of eccentric mitral regurgitation is present. Left ventricular dimensions are normal. Left ventricular systolic function is hyperdynamic. The aorta and aortic valve appear normal, though trace aortic insufficiency is normal. Right atrial and right ventricular dimensions are normal. The tricuspid valve leaflets are mildly thickened, and a mild jet of tricuspid regurgitation is present. TR velocity does not suggest the presence of pulmonary hypertension. The pulmonary artery and pulmonic valve appear normal, though trace pulmonic insufficiency is present. No shunting lesions are visualized. No pericardial effusion or cardiac masses are seen.

PATIENT

Hula Lert

LA - 28.3 mm
LVIDd - 28.0 mm
LVIDs - 19.6 mm
FS - 30%
RA - 16.9 mm
LVOT - 1.20 m/s
RVOT - 0.71 m/s
TR - 2.44 m/s

SPECIES

Canine

ASSESSMENT/RECOMMENDATIONS

Degenerative mitral and tricuspid valve disease

BREED

Dachshund

This examination demonstrates mild regurgitation of blood across Hula's mitral and tricuspid valves resulting from degenerative valve disease. The hemodynamic effects of each of the regurgitations also appear to be mild, as Hula does not have secondary dilation of any of her cardiac chambers. As such, Hula's valvular diseases appear to be well-compensated, and her coughing episode does not appear to be cardiogenic in origin.

SEX

FS

Thoracic radiographs may be warranted to further evaluate Hula's cough.

No therapy is recommended at this stage of Hula's valvular diseases.

A recheck echocardiogram is recommended in 6 months to monitor for disease progression.

AGE

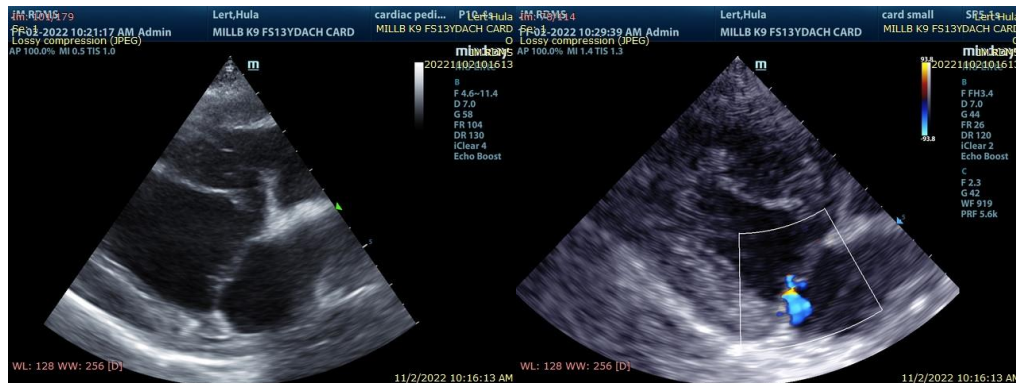
13 y

WEIGHT

15 lb

HOSPITAL NAME

Millburn VH



REFERRING VET

Dr. Turowsky



The information and recommendations provided are based on the images presented by the referring veterinarian. No evaluation can be communicated regarding pathology that was not visible in the image/video clips provided.

DATE

11/2/22

Thank you for this referral. If the clinical or image interpretation does not parallel your findings or if I can be of any further assistance please contact me.

PERFORMED BY:

Jessica Miller

Keith Blass, DVM, MS, DACVIM (Cardiology)
KeithBlass@gmail.com
631-804-5754

INTERPRETED BY

Keith Blass, DVM,
MS, DACVIM
(Cardiology)

PATIENT

Hula Lert

SPECIES

Canine

BREED

Dachshund

SEX

FS

AGE

13 y

WEIGHT

15 lb

HOSPITAL NAME

Millburn VH

REFERRING VET

Dr. Turowsky